

Acute superior vena cava obstruction due to tight pericardial closure following congenital defect repair

Prashant N. Mohite, Sandip Singh Rana, Jitendeep Singh, Kunal D. Kotkar,
G. D. Puri, S. K. Sodhi

*Department of Cardiothoracic and Vascular surgery, Post Graduation Institute of Medical Education and
Research, Sector - 12, Chandigarh - 160 012, India*

*Address for correspondence: Mr. Prashant N. Mohite, 6 Parkwood House, Harefield Hospital, Harefield,
Middlesex, UB9 6JH, United Kingdom. E-mail: drprashantis@rediffmail.com*

ABSTRACT

The obstruction of the superior vena cava (SVC) of acute onset nature following surgery is a rare and serious condition. The tight closure of the pericardium over the heart during surgical procedures may cause external compression on the SVC. Echocardiography and Computed tomography (CT) scan aids in the diagnosis. Cutting open the pericardial stitches relieves the condition.

Key words: Pericardial closure, superior vena cava, superior vena cava obstruction

INTRODUCTION

Superior vena cava (SVC) obstruction of acute onset is uncommon after cardiac surgery. It needs thorough speculation by means of radio-imaging techniques towards the etiology.

Text: A two year old male child was hospitalized with chief complaints of repeated lower respiratory tract infections and poor weight gain. Physical examination revealed a pan-systolic murmur on left parasternal border. The echocardiography showed a single, 9 mm perimembranous defect and mild pulmonary valvular stenosis. The patient was taken up for surgery. The pericardium was opened to the right of the midline such that a patch could be harvested for widening of pulmonary annulus, if required. Aortic and bi-cavalcannulation was done to initiate cardio-pulmonary

bypass. The Hegar's dilator of 17 mm easily passed across the pulmonary valve abating the need of a right ventricular outflow tract repair. Ventricular septal defect was closed with a polytetrafluoroethylene patch. The child was weaned off bypass and pericardium was closed over the heart. His hemodynamic parameters including the arterial pressure and central venous pressure (CVP) were within normal range during chest closure and shifting to the recovery bed.

Post operatively, CVP started rising slowly and it reached up to 20 millimetres of mercury in two hours. The face became puffy and appreciable oedema was noticed over the eyelids within next 12 hours. Chest radiograph showed a shadow on right upper heart border [Figure 1]. Echocardiography showed flow turbulence at the junction of SVC and right atrium. CT was done to find out the cause of obstruction which showed acute narrowing of SVC at its entry into right atrium [Figure 2]. There was no intravascular thrombus or extravascular clot or foreign material causing the obstruction.

The child was taken up for re-exploration and the sternum was reopened. The SVC and the innominate vein were tense and non-collapsible. An obvious kinking of SVC was seen at its entry into the right atrium due to tight closure

Access this article online	
Quick Response Code: 	Website: www.jcdronline.com
	DOI: 10.4103/0975-3583.95369

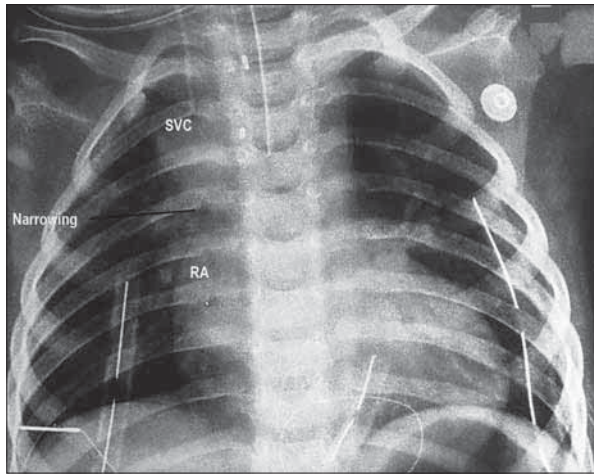


Figure 1: Chest radiograph showing shadow on right upper heart border. SVC (Superior vena cava), RA (Right atrium)

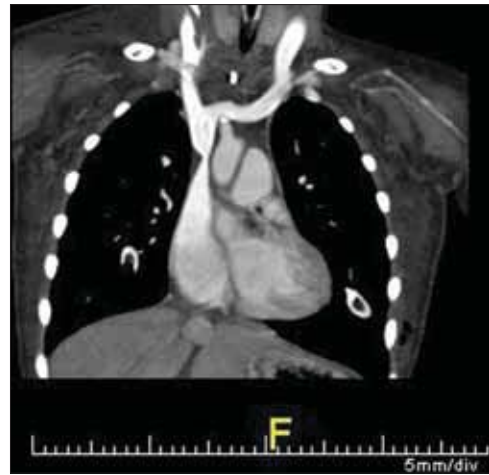


Figure 2: Computed tomography scan showing narrowing of superior vena cava at its entry into right atrium

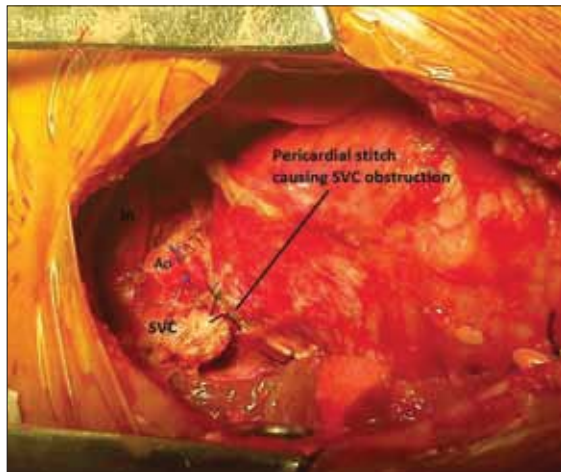


Figure 3: Tight closure of pericardium. SVC (Superior vena cava), In (Innominate vein)

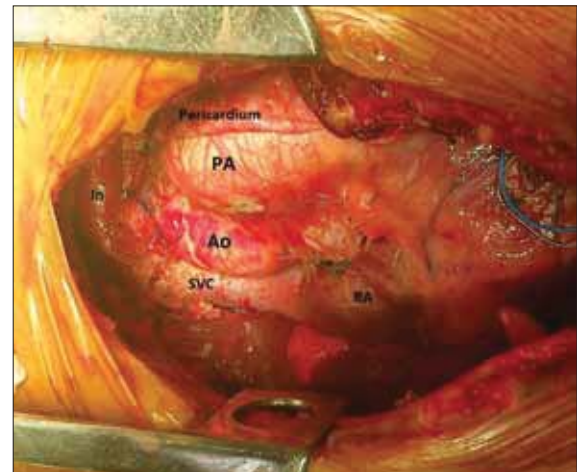


Figure 4: After cutting open pericardial sutures. SVC (Superior vena cava), In (Innominate vein), RA (Right atrium), Ao (Aorta)

of pericardium [Figure 3]. As soon as the pericardial sutures were cut, the pressure in SVC fell dramatically from 22 to 12 mm [Figure 4]. The innominate vein and SVC became soft. The sternum was closed and the child was ventilated overnight. The facial and eyelid oedema decreased significantly in 24 hours. The child was weaned off the ventilator and made an uneventful recovery.

DISCUSSION

Acute onset SVC obstruction is a serious condition and needs urgent attention. SVC obstruction can be caused by extravascular compression or intravascular obstruction. The most common cause in the recent era is acute thrombotic occlusion of SVC following central venous catheterisation.^[1,2] Incidence following cardiac surgery are very low in number; however, cases are reported about acute SVC obstruction after the repair of sinus venosus atrial septal defect and the Senning's repair for transposition of great arteries.^[3] Direct

cannulation of the SCV and closure of the hole by purse-string may cause SVC obstruction. In the present article case, tight closure of the pericardium caused the obstruction of the SVC which led to acute SVC syndrome.

Acute SVC obstruction presents as dyspnoea, swelling of face, neck and upper extremity, and engorgement of neck and facial veins.^[1,4] In the present article, the child was on ventilator with all monitoring lines in. The central venous pressure remained above 20 mm of mercury after the surgery. There was gross facial and obvious eyelid swelling. The CVP was within normal limits immediately after surgery, and this may be because of the hypovolemia related to surgery. With the volume replacement in recovery unit after surgery, the CVP rose and stayed at higher level due to obstruction in SVC.

Echocardiography is a non-invasive and first modality of investigation which can diagnose the condition along

with possible aetiologies. CT scan gives the objective evidence and cause of SVC obstruction.^[5] In the present case, both Echocardiography and CT scan were helpful in diagnosing the condition; however, failed to provide the aetiology. Though surgical repair is the gold standard in the treatment of acute SVC obstruction, it can also be treated with covered stent or balloon dilatation.^[3,6] In the present article, we found that the tight pericardium was obstructing the SCV flow and simply, cutting open of the pericardium relieved the obstruction.

CONCLUSION

This case demonstrates an unusual post operative course of events and physical findings in which the causative factor for acute SVC obstruction was tight pericardial closure. The insight gained was to always assure a loose pericardial closure.

ACKNOWLEDGEMENT

Authors are not funded by any external source.

REFERENCES

1. Qanadli SD, Mesurolle B, Sissakian JF, Chagnon S, Lacombe P. Implanted central venous catheter-related acute superior vena cava syndrome: Management by metallic stent and endovascular repositioning of the catheter tip. *Eur Radiol* 2000;10:1329-31.
2. Ketharanthan V, McConshie I, Mullerworth M. Acute thrombotic occlusion of the superior vena cava treated successfully by emergency thrombectomy. *Thorax* 1971;26:744-6.
3. Rossi FR, Manica JL. Relief of severe immediate post operative superior venacavasthenosis with coveredstent: Case report with midterm follow up. *Catheter Cardiovasc Interv* 2009;74:1085-8.
4. Parrish JM, Marschke 1W Jr, Dines DE, Lee RE. Etiologic considerations in superior vena cava syndrome. *MayoClin Proc* 1981; 56:407-13
5. Qanadli SD, El Hajjam M, Bruckert F, Judet O, Barre O, Chagnon S, *et al.* Helical CT phlebography of the superior vena cava: Diagnosis and evaluation of venous obstruction. *AJR Am J Roentgenol* 1999;172: 1327-33.
6. Benson LN, Yeatman L, Laks H. Balloon dilatation for superior vena caval obstruction after the senning procedure. *Cathet Cardiovasc Diagn* 1985;11:638.

How to cite this article: Mohite PN, Rana SS, Singh J, Kotkar KD, Puri GD, Sodhi SK. Acute superior vena cava obstruction due to tight pericardial closure following congenital defect repair. *J Cardiovasc Dis Res* 2012;3:135-7.

Source of Support: Nil, **Conflict of Interest:** None declared.

Announcement

Android App



Download
**Android
application**

FREE

A free application to browse and search the journal's content is now available for Android based mobiles and devices. The application provides "Table of Contents" of the latest issues, which are stored on the device for future offline browsing. Internet connection is required to access the back issues and search facility. The application is compatible with all the versions of Android. The application can be downloaded from <https://market.android.com/details?id=comm.app.medknow>. For suggestions and comments do write back to us.